



# Anti-Inflammatory, Antioxidant and Neuroprotective Effects of Niacin on Mild Traumatic Brain Injury in Rats

Dilan OZAYDIN<sup>1</sup>, Pinar KURU BEKTASOGLU<sup>2</sup>, Turkan KOYUNCUOGLU<sup>3</sup>, Seyma COLAKOGLU OZKAYA<sup>4</sup>, Ayca KARAGOZ KOROGLU<sup>5</sup>, Dilek AKAKIN<sup>6</sup>, Can ERZIK<sup>4</sup>, Meral YUKSEL<sup>7</sup>, Berrak C. YEGEN<sup>8</sup>, Bora GURER<sup>9</sup>

<sup>1</sup>University of Health Sciences, Kartal Dr. Lutfi Kirdar Education and Research Hospital, Department of Neurosurgery, Istanbul, Turkiye

<sup>2</sup>Sivas Numune Hospital, Department of Neurosurgery, Sivas, Turkiye

<sup>3</sup>Biruni University Faculty of Medicine, Department of Physiology, Istanbul, Turkiye

<sup>4</sup>Marmara University, Institute of Health Sciences, Department of Medical Biology, Istanbul, Turkiye

<sup>5</sup>Istinye University School of Medicine, Department of Histology and Embryology, Istanbul, Turkiye

<sup>6</sup>Marmara University School of Medicine, Department of Histology and Embryology, Istanbul, Turkiye

<sup>7</sup>Marmara University Vocational School of Health-Related Services, Department of Medical Laboratory, Istanbul, Turkiye

<sup>8</sup>Marmara University School of Medicine, Department of Physiology, Istanbul, Turkiye

<sup>9</sup>Istinye University Faculty of Medicine, Department of Neurosurgery, Istanbul, Turkiye

\*This study was presented at Turkish National Neuroscience Congress, 2021 and International Live Conference on Neurosurgery, 2022

**Corresponding author:** Pinar KURU BEKTASOGLU ✉ drpinarkuru@gmail.com

## ABSTRACT

**AIM:** Niacin is a water-soluble vitamin. The effects of niacin on inflammation, oxidative stress and apoptotic processes observed after mild traumatic brain injury (TBI) were studied in this study.

**MATERIAL and METHODS:** Wistar albino male rats were randomly divided into control (n=9), TBI + Placebo group (n=9), TBI + niacin (500 mg/kg; n=7) groups. Mild TBI was performed under anesthesia by dropping a 300 g weight from a height of 1 meter onto the skull. Behavioral tests were applied before and 24 hours after TBI. Luminol and lucigenin levels and tissue cytokine levels were measured. Histopathological damage was scored in brain tissue.

**RESULTS:** After mild TBI, luminol (p<0.001) and lucigenin (p<0.001) levels were increased, and their levels were decreased with niacin treatment (p<0.01-p<0.001). An increased score was obtained with trauma in the tail suspension test (p<0.01), showing depressive behavior. The number of entries to arms in Y-maze test were decreased in TBI group compared to pre-traumatic values (p<0.01), while discrimination (p<0.05) and recognition indices (p<0.05) in object recognition test were decreased with trauma, but niacin treatment did not change the outcomes in behavioral tests. Levels of the anti-inflammatory cytokine IL-10 were decreased with trauma (p<0.05) and increased with niacin treatment (p<0.05). The histological damage score (p<0.001) was increased with trauma, and decreased with niacin treatment in the cortex (p<0.05) and hippocampal dentate gyrus region (p<0.01).

**CONCLUSION:** Niacin treatment after mild TBI inhibited trauma-induced production of reactive oxygen derivatives and elevated the anti-inflammatory IL-10 level. Niacin treatment ameliorated the histopathologically evident damage.

**KEYWORDS:** Brain trauma, neuroprotection, niacin, vitamin B3

Dilan OZAYDIN : 0000-0002-1525-7613  
Pinar KURU BEKTASOGLU : 0000-0001-9889-9955  
Turkan KOYUNCUOGLU : 0000-0003-4749-9470  
Seyma COLAKOGLU OZKAYA : 0000-0003-0103-5734  
Ayca KARAGOZ KOROGLU : 0000-0002-2532-8091

Dilek AKAKIN : 0000-0002-1781-3708  
Can ERZIK : 0000-0002-7914-1169  
Meral YUKSEL : 0000-0002-4760-3306  
Berrak C. YEGEN : 0000-0003-0791-0165  
Bora GURER : 0000-0003-1500-6184

## INTRODUCTION

Traumatic brain injury (TBI) cause morbidity and each year nearly 50 million people have TBI all over the world (25). TBI accounts for a significant proportion of young adult deaths worldwide (25). After mechanical damage, primary injury starts and damages blood vessels, neurons, and glial cells (36). Secondary injury results from trauma-related delayed processes resulting in inflammation, lipid peroxidation, oxidative stress, ionic imbalance due to energy deficiency, apoptosis, and excitotoxicity (23,36). All treatment options currently used in TBI are aiming to reverse secondary injury mechanisms. Although there are numerous conducted studies to ameliorate secondary damage in TBI, but there is no proven treatment available in clinical use (2,15,29,30,47).

Niacin (vitamin B3) is a water soluble vitamin that includes two vitamers, nicotinamide and nicotinic acid (12). Nicotinamide adenine dinucleotide (NAD) and the nicotinamide adenine dinucleotide phosphate (NADP) are crucial coenzymes for oxidative reactions, and regulation of energy metabolism. These coenzymes also play roles in non-redox signaling pathways and regulate critical biological functions (i.e. DNA repair, cell death) (12). On the other hand, balance between nicotinamide and NAD<sup>+</sup> is important for neuronal health (10). Niacin is a potent neuroprotective and neurorestorative agent and its beneficiary effects were shown in neurodegenerative (Alzheimer's and Parkinson disease) and neuropathological conditions (TBI, ischemic injuries, headache, and psychiatric conditions) (10,12). Therapeutic activity of niacin was previously shown in a TBI model (14). In a controlled cortical impact model, niacin was shown to reduce the infarct size, while sensory, motor, and cognitive skills were improved by niacin (43).

In the current study, the neuroprotective effects of niacin after acute administration in mild TBI were studied with different indicators. It is hypothesized that niacin treatment given following mild TBI will exert neuroprotective activity by diminishing oxidative stress, inflammation, and apoptosis, and have an ameliorative effect on memory and corticospinal tract functions.

## MATERIAL and METHODS

Marmara University Animal Care and Use Committee approved this study (46.2019.mar). European Communities Council Directive, September 22, 2010 (2010/63/EU) for the experimental use were followed for animal care and all experiments. The ARRIVE guidelines were used for reporting this study. Twenty-five adult male Wistar albino rats weighing 250–400 g were used. Animals were housed in standardized room conditions, were fed standard laboratory chow and had free access to water.

The rats were randomly assigned to one of three groups:

1. Control group (n=9): Following the skin incision a single intraperitoneal (ip) dose of saline (0.1 ml/100 g) at 15 minutes after surgery were applied.

2. TBI + Placebo group (n=9): Following TBI and a single ip dose of saline (0.1 ml/100 g) at 15 minutes after TBI were applied.
3. TBI + Niacin group (n=7): Following TBI and a single ip dose of 500 mg/kg Niacin at 15 minutes after TBI were applied. Dose was adjusted from previously published literature (14).

### Anesthesia, Induction of TBI, and Tissue Collection

Intraperitoneal injection of a combination of 50 mg/kg ketamine (Ketalar, Parke Davis, Turkey) and 0.5 mg/kg chlorpromazine (Largactil, Eczacıbaşı, Turkey) were used for anesthesia. Rats breathed spontaneously during experiments. A mild TBI model, described by Marmarou et al. (27) and modified by Ucar et al. (41) was preferred for the induction of TBI. Ucar et al. (41) reported in their studies that a 300 g lead object that was allowed to free-fall from a 1-m height on to the metal disc over the skull of the rat created a mild TBI. We also used this model for induction of mild TBI in rats (18,19).

All the animals were sacrificed at 24 hours after TBI, and the brains were immediately collected. Certain parts of the brain were obtained from each animal for the analysis of each parameter as previously published (18,19).

### Biochemical Investigations

#### Luminol and Lucigenin Level Measurements in Brain Tissue

Chemiluminescence (CL) measure reactive oxygen radicals using luminol and lucigenin as enhancer probes. Detailed explanation of these measurements was previously reported (17,18). Results were presented as relative light units/mg tissue (rlu/mg).

#### Enzyme-Linked Immunosorbent Assay Measurements

The levels of interleukin (IL)-1 $\beta$ , IL-6, tumor necrosis factor- $\alpha$  (TNF- $\alpha$ ), IL-10, transforming growth factor- $\beta$  (TGF- $\beta$ ), caspase 3, and cleaved caspase 3 in the brain tissue were measured using commercial enzyme-linked immunosorbent assay kits (Sunlong Biotech Co. Ltd., China). Manufacturer's guidelines were followed for using the kits. Supernatants of tissue homogenates were used for the measurements.

#### Histopathological Examinations with Light Microscopy

The brain tissue was fixed in the 4% paraformaldehyde in phosphate buffer (pH 7.4) for 24 hours at 4°C. Explanation of histopathological examination was previously reported (7,17,18). Investigators blinded to study groups scored the samples.

#### Behavioral Tests

The behavioral tests were performed before TBI and at 24 hours after TBI. Investigators blinded to study groups scored the findings.

#### Novel Object Recognition Test

For short-term memory evaluation, novel object recognition test was used. Cortical and hippocampal lesions exert

changes in test results (1). Detailed explanation of the object recognition test was previously reported (17,18,24). Increase in difference score, recognition index and positive discrimination index scores indicated improvement of cognitive functions.

#### Y-Maze Test

The Y maze is characterized 120-degree angle branches, where the rats choose the arms. The number of entries into the arms and spontaneous alternation are the evaluated parameters to evaluate spatial working memory (28).

#### Corticospinal Function Evaluation

The loss of corticospinal functions was measured with limb claspings (28). The rat was suspended by the tail for 5-10 seconds, during which it was videotaped, and two independent observers evaluated the recordings between 0-4. Higher scores indicate immobilization.

#### Modified Bederson Neurological Examination Score

Motor and behavioral deficits was assessed with a 20-point neuro-scoring system (3,40). Higher scores indicated the neurological disorder.

#### Statistical Analysis

Data were analyzed using GraphPad Prism 8.0 (GraphPad Software, San Diego, CA, USA) and expressed as means  $\pm$  SEM. Analysis of biochemical and histological data was performed using one-way analysis of variance, followed by Tukey's posthoc test. Values of  $p < 0.05$  were considered to be statistically significant.

## RESULTS

### Biochemical Results

#### Chemiluminescence Results

Luminol levels were significantly increased in the TBI + placebo group when compared to the control group ( $p < 0.001$ ). In niacin-treated TBI group, a significant decrease was observed

in luminol levels when compared to the TBI + placebo group ( $p < 0.001$ ) (Figure 1A). There was a significant increase in lucigenin levels in the TBI + placebo group as compared to the control group ( $p < 0.001$ ). Increased oxidative stress and inflammation after TBI increased luminol and lucigenin levels. On the other hand, a significant decrease in lucigenin levels was observed in the niacin-treated TBI group when compared to the TBI + placebo group ( $p < 0.01$ ) (Figure 1B), indicating that niacin has antioxidant and anti-inflammatory activities in TBI.

#### ELISA Results

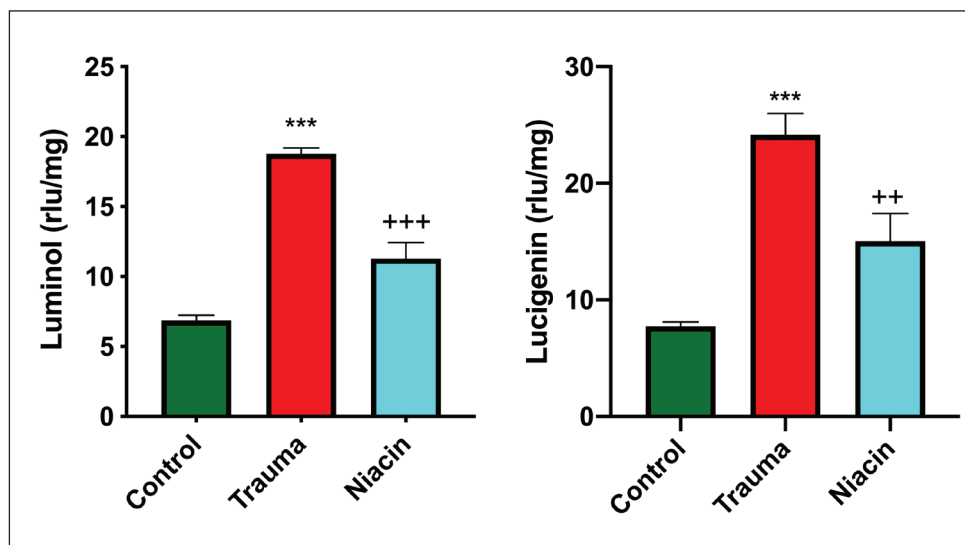
IL-1 $\beta$ , IL-6, TNF- $\alpha$ , and TGF- $\beta$  levels in the brain tissue did not show significant difference (Figure 2A-E). The inflammatory cytokines showed an increasing trend in the TBI + placebo group, but the TBI + niacin group had similar values with the control group.

There was a significant decrease in IL-10 levels in the TBI + placebo group when compared to control group ( $p < 0.05$ ). A significant increase in IL-10 level was observed in the TBI + niacin group when compared to the TBI + placebo group ( $p < 0.05$ ).

An increase was observed in the caspases in the TBI + placebo group. However, no significant difference was present for caspases among control, TBI + placebo, and TBI + niacin (Figure 3 A-B).

#### Histopathological Results

Cortex, hippocampal dentate gyrus (DG), and CA3 regions were investigated with hemotoxylin and eosin staining for neuronal cell damage. In all these regions of the control group, neurons showed a uniform morphology, regular neuropil structure and large nuclei with obvious nucleolus structures (Figure 4A-C). Neuronal injury, irregularity of cell structures, cytoplasmic deterioration and pycnotic cell nuclei were seen in all of these areas in the TBI + placebo group compared to the control group (Figure 4D-F). These histopathological changes were less in the niacin-treated TBI group (Figure 4G-I).



**Figure 1: A)** Luminol and **B)** Lucigenin (rlu/mg) levels of study groups (according to the control group \*\*\*:  $p < 0.001$ , according to the TBI + placebo group ++:  $p < 0.01$ , +++:  $p < 0.001$ ).

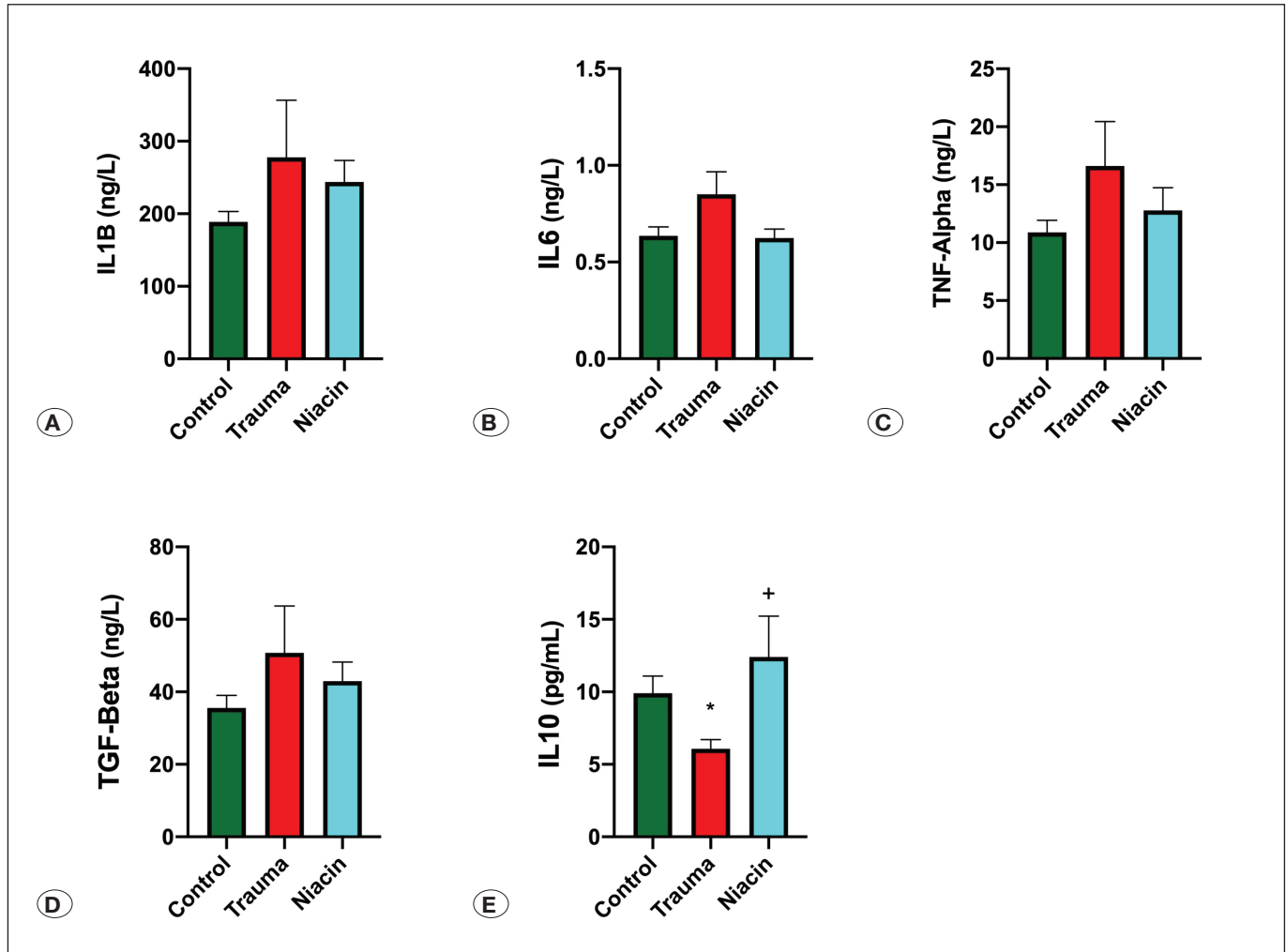


Figure 2: A) IL-1b, B) IL-6, C) TNF-Alpha, D) TGF-Beta, E) IL-10 levels of study groups (According to the control group \*:  $p < 0.05$ , according to the TBI + placebo group +:  $p < 0.05$ ).

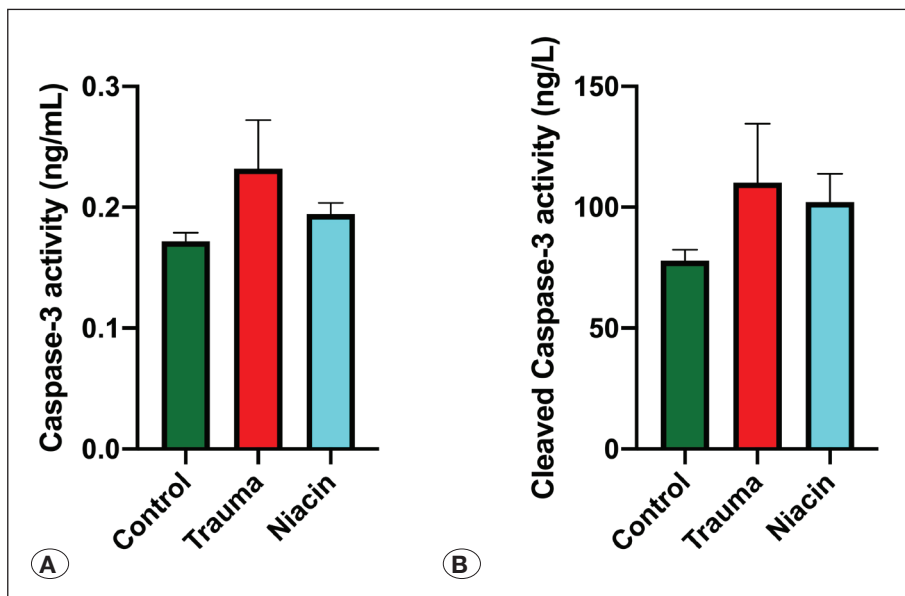
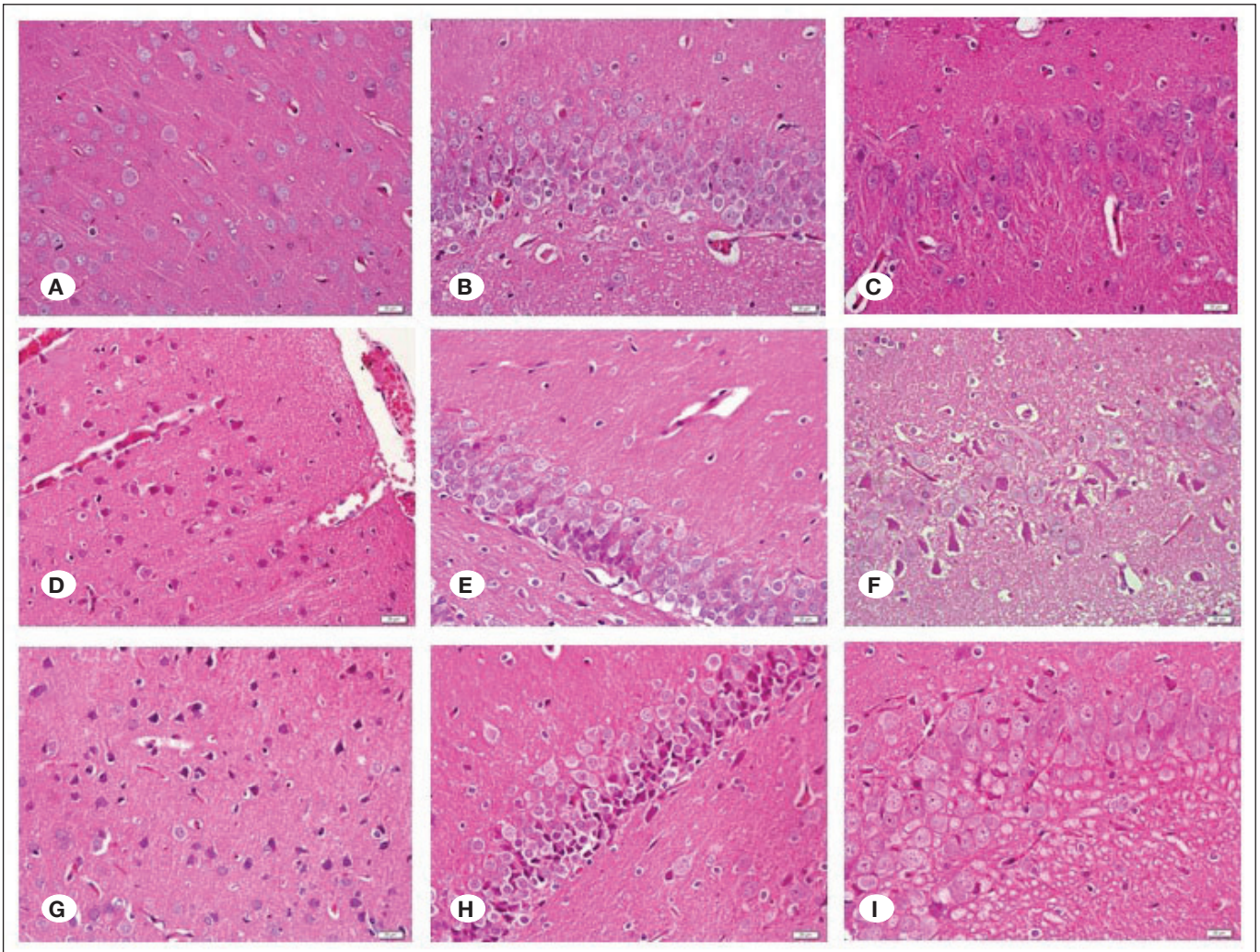


Figure 3: A) Caspase-3, and B) Cleaved caspase-3 levels of study groups.



**Figure 4:** **A-C)** Representative sections of the cortex, hippocampal dentate gyrus (DG), and CA3 regions, in the control group. **D-F)** Representative sections of the cortex, hippocampal DG, and CA3 regions in the TBI + placebo group. **G-I)** Representative sections of the cortex, hippocampal DG, and CA3 regions in the niacin group. H&E stain. Scale bar: 50 µm.

In the cortex, the histological damage score was increased significantly in the TBI + placebo group when compared to the control group ( $p < 0.001$ ), while the histological damage score showed a significant decrease in the niacin-treated TBI group, when compared to the TBI + placebo group ( $p < 0.05$ ) (Figure 5A).

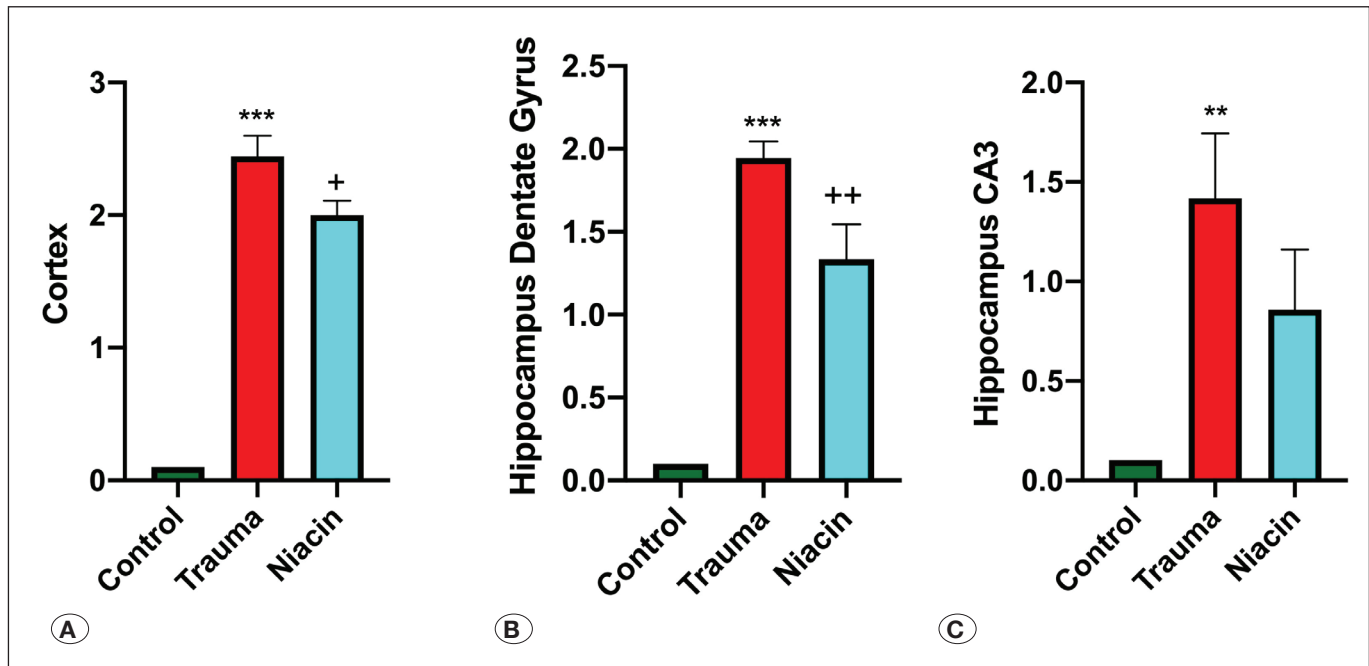
In the hippocampal DG, the histological damage score was found to be increased in the TBI + placebo group as compared to the control group ( $p < 0.001$ ). The histological damage score was decreased in the niacin-treated TBI group when compared to the TBI + placebo group ( $p < 0.01$ ) (Figure 5B).

In the hippocampal CA3 region, the histological damage score in the TBI + placebo group was significantly increased when compared to the control group ( $p < 0.01$ ). A decrease was seen in this damage score of the niacin-treated TBI group, when compared to the TBI + placebo group (not significant) (Figure 5C).

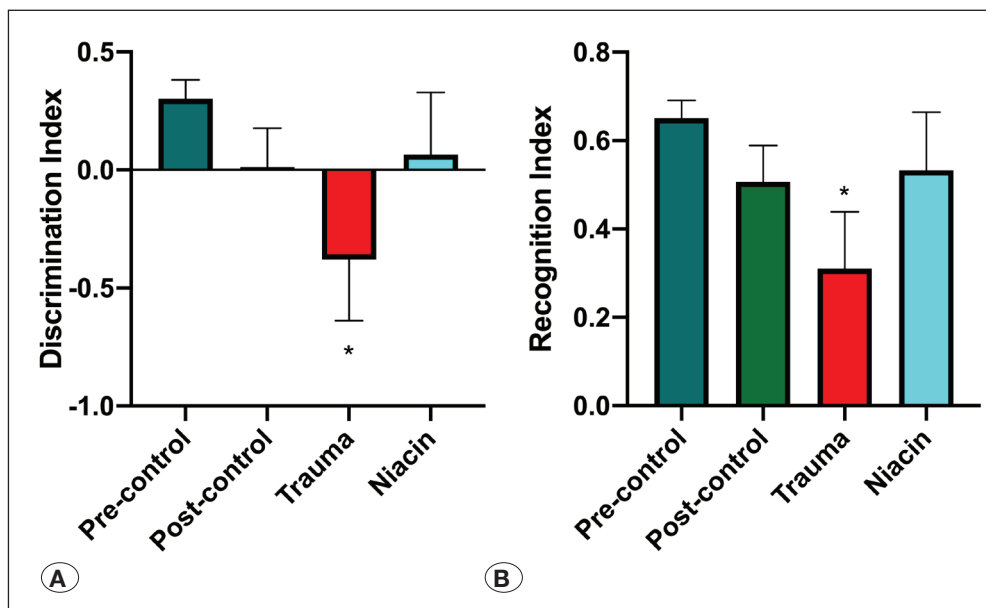
## Behavioral Tests

### Novel Object Recognition Test

The discrimination index scores of the TBI + placebo group were negative, and there was a significant difference in the TBI + placebo group when compared to the pre-control values ( $p < 0.05$ ). Similarly, there was a significant decrease in the recognition index of the TBI + placebo group as compared to the control group ( $p < 0.05$ ). Although the discrimination index (Figure 6A) and the recognition index (Figure 6B) scores of the niacin-treated TBI group were elevated when compared to the TBI + placebo group, no significant difference was present, but the scores were similar to the pre-control values. The discrimination and recognition indices showed a decreased tendency in the TBI + placebo group when compared to the pre-control group. In the niacin-treated group, values were similar to those of the control values (not significant).



**Figure 5:** Hematoxyline-eosin (HE) staining histological damage scores among experimental groups **A)** Cortex, **B)** Hippocampal dentate gyrus, **C)** Hippocampal CA3 region (according to the control group; \*\*:  $p < 0.01$ , \*\*\*:  $p < 0.001$ ; according to the TBI + placebo group; +:  $p < 0.05$ , ++:  $p < 0.01$ ).



**Figure 6:** **A)** Discrimination index, and **B)** Recognition index among study groups, novel object recognition test indices (according to the pre-control group; \*:  $p < 0.05$ ).

**Y Maze Test**

A decrease was seen in the number of entries to the arms in the TBI + placebo and niacin-treated TBI groups when compared to the pre-control and post-control group values (not significant, Figure 7A). When spontaneous alternation was analyzed, no significant difference was present among the experimental groups (Figure 7B). The number of entries was decreased in the TBI + placebo and niacin-treated TBI group when compared to pre-control and post-control values.

This finding was compatible with the freezing behaviour. The spontaneous alternation percentages were not significantly different among groups.

**Tail Suspension Test**

A significant increase was seen in the tail suspension test score in the TBI + placebo group when compared to the control group ( $p < 0.01$ ), while the test scores of the niacin-treated TBI group were reduced, but no significance was present with respect to the TBI + placebo group (Figure 8).

### Modified Bederson Neurological Examination Score

In the TBI + placebo group only one of the rats had 1 as the examination score, but all subjects in the control and niacin-treated TBI group were scored as 0. Thus, no significant difference was present among the groups.

## DISCUSSION

Mild form of TBI accounts up to 95% of all TBI cases (39). Mild TBI-related morbidity includes cognitive, motor, sensory and emotional impairments (35). Mostly, full recovery after mild TBI is the natural course, but the presence of persistent symptoms for months or years following trauma is also possible (42). In this research, the neuroprotective effects of niacin treatment in a mild TBI model were investigated. When compared with the previous studies that have investigated niacin treatment for TBI, we preferred the use of a diffuse TBI model that was described by Marmarou (27) and modified by Ucar et al (41). Behavioral parameters that we have evaluated also differ from already investigated parameters in the previous studies. In this study, anti-inflammatory and antioxidant activity of niacin in mild TBI was shown with the inhibition of luminol and lucigenin levels and elevation in IL-10 levels. Histopathological evidence also supported the hypothesis that niacin treatment in acute period results in the amelioration of mild TBI in the cortical and hippocampal DG regions.

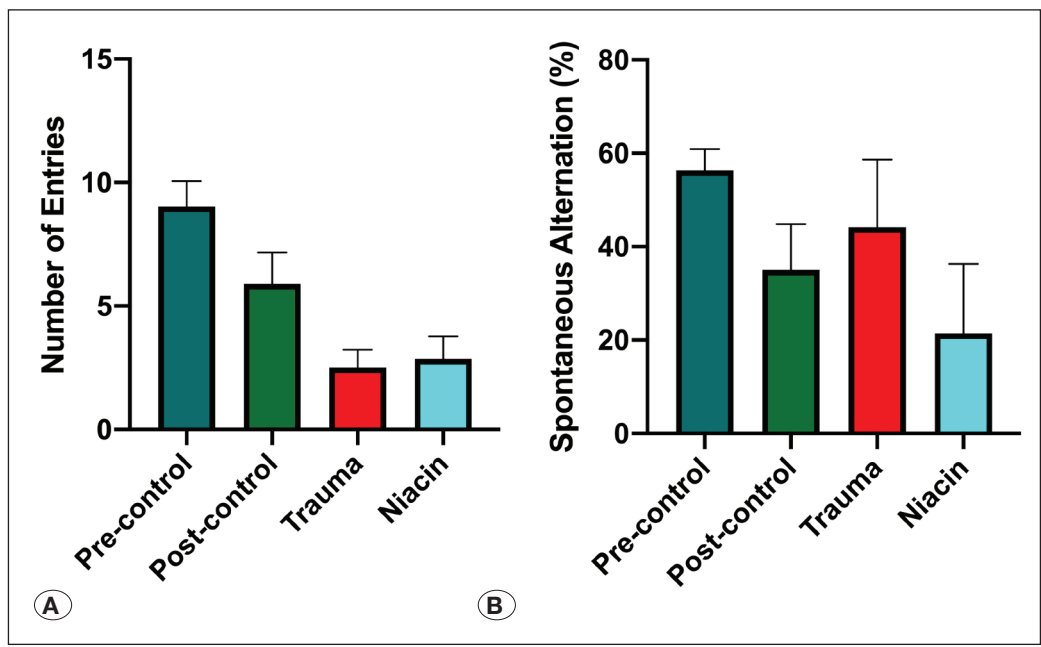
Niacin, which is a safe and effective supplement for ischemic and traumatic brain injuries (12), was previously shown to improve TBI-related behavioral deficits and functional recovery (14). NADH hyperoxidation, which is seen after TBI due to impaired NAD<sup>+</sup>/NADH recycling, is associated with diminished neural recovery. This can be reverted and mitochondrial energy metabolism may be restored with increasing NAD<sup>+</sup> levels (9). Accordingly, nicotinamide pre-treatment increases mitochondrial function, and aids neuronal recovery (37). Niacin decreases microglial activation, modulates inflammatory and immune genes, increases neurotrophic factors, decreases DNA damage, decreases oxidative stress, increases ATP content, restores NAD<sup>+</sup>/NADH balance and mitochondrial function and biogenesis, and changes macrophage phenotype (12). Niacin inhibits angiotensin II-induced reactive oxygen species, TNF- $\alpha$ -induced NF- $\kappa$ B activation, and monocyte chemotactic protein-1 secretion (11). In a cardiac arrest model, vitamin B<sub>3</sub> treatment ameliorated microglial activation in corpus callosum, axonal injury, hippocampal apoptosis, and improved neurological deficits (21). In the brain tissue, NAD(P) restoration and oxidative stress suppression, caspase-3 cleavage and mitogen-activated protein kinase signaling decrease are the nicotinamide-dependent mechanisms responsible from this amelioration (21). In a stroke model, niacin treatment in the form of niaspan was reported to increase synaptic plasticity and axonal growth (5). In TBI models, niacin treatment has decreased behavioral deficits and improved long-term functional recovery (13,14,38,43,44). Co-administration of niacin with progesterone in TBI model (33,34,45) or with selenium in cardiac arrest model (20) has also synergistically attenuated cortical cell injury and increased functional recovery. In parallel with these reports,

elevated luminol and lucigenin levels in TBI + placebo group were decreased by niacin treatment. Luminol and lucigenin levels are commonly studied as indicators of oxidative stress and inflammation (7,18,19). Although anti-oxidant activity of niacin was previously shown in cerebral ischemia model (21), its antioxidant action in a TBI model was not shown before. The current findings support the literature that niacin is a potent anti-oxidant and anti-inflammatory agent, which could be preferred in the alleviation of acute mild TBI.

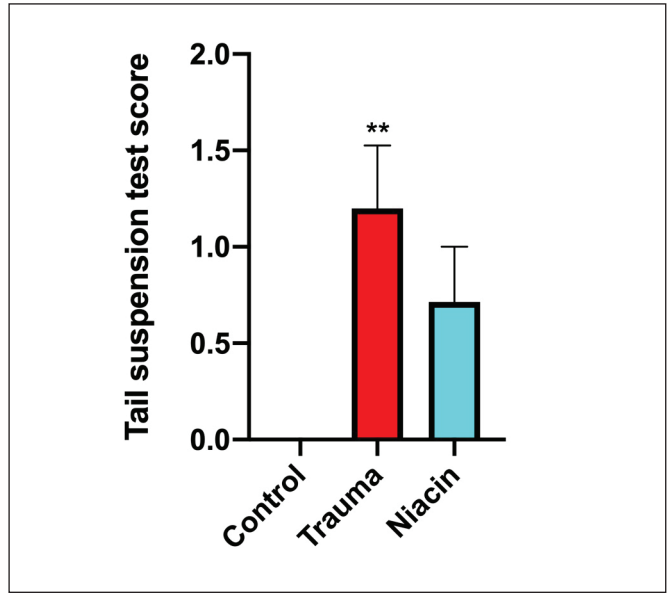
Following TBI, activated microglia release pro-inflammatory cytokines (23,32) and the IL-1 $\beta$  and TNF- $\alpha$  levels are positively correlated with the severity of TBI (16,23,32). Excess amount of these cytokines is associated with decreased neuronal survival. Following TBI, IL-1 $\beta$  mRNA expression peaks at 12-24 hours (32), while IL-6 and TNF- $\alpha$  levels peak around 2-8 hours after TBI (23,32). However, others have shown that TNF- $\alpha$  levels do not change in the mild form of TBI (17). In the current study, IL-1 $\beta$ , IL-6, TNF- $\alpha$ , and TGF- $\beta$  levels were increased at the 24th hour of the TBI, but no significant difference was evident among the cytokine levels of TBI + placebo and TBI + niacin groups. It is possible that the diffuse mild TBI model used in the present study has not increased cerebral IL-1 $\beta$ , IL-6 and TNF- $\alpha$ , and TGF- $\beta$  cytokine levels significantly (17,46). Another possibility is that these cytokine levels may have returned to normal values at the 24th hour after TBI (46). On the other hand, cerebral level of IL-10, which is accepted as an anti-inflammatory cytokine (31), was significantly decreased in the TBI + placebo group, while it was significantly increased in the niacin-treated TBI group. This may show the anti-inflammatory action of acute niacin administration in mild TBI model.

Apoptotic cascades are regulated mainly with caspases (8). Caspase-3 was previously shown to be increased within 24 hours following TBI (7). Cleaved caspase-3 is the degraded form of caspase-3 (8). Since decreased NAD<sup>+</sup> levels were associated with neuronal apoptosis, niacin treatment is expected to restore NAD<sup>+</sup> and thereby exert an anti-apoptotic activity (10). Nicotinamide treatment reduces NADH levels, restores ATP levels, supports DNA stability, prevents apoptosis, and improves neuronal function (10,26). Nicotinamide was shown to prevent apoptosis by inhibiting caspase 1, 3, and 8 and cytochrome C release during cellular damage (26,22). In the current study, caspase-3 and cleaved caspase-3 levels showed increased activity in the TBI + placebo group; but there was no significant difference among the control and TBI + placebo groups. The TBI + niacin group also did not show any significant difference. It may be hypothesized that caspase -3 and cleaved caspase-3 were not yet increased to make a significant difference or the activated cascades could be reverted to their baseline values (18,19).

Mild form of TBI mostly presents with cognitive or behavioral problems, rather than major neurological deficits that are seen in severe or moderate form of TBI (4). Neurological and cognitive changes are also important parameters when we investigate the effects of a potential pharmacological agent in mild TBI. In the modified Bederson neurological examination score, no significant difference was seen among the groups.



**Figure 7:** **A)** The change in the number of entries into the arms, **B)** The percentage of spontaneous alternation among the study groups.



**Figure 8:** Tail suspension test scores among study groups (According to control group \*\*:p<0.01).

Since the severity of TBI deteriorates the neurological outcomes (27,41), it is possible that mild TBI has not caused any significant changes in neurological outcomes. Niacin was previously reported to improve functional recovery after TBI (14). The novel object recognition test evaluate short-term recognition memory, distinguishing novel, or remembering, and learning (6,9). Discrimination and recognition indices were decreased in the TBI + placebo group and the differences were significant. However, increased levels of discrimination and recognition indices in the niacin-treated TBI group, which have not reached to statistical significance, suggest a tendency in the amelioration of recognition memory dysfunction. Y maze

test evaluates spatial working memory (28). In this study, the number of entries to the arms was decreased in the TBI + placebo group as compared to pre-procedure values, showing the cognitive dysfunction. In another TBI study, the time to find the platform in the Morris water maze test was prolonged in the TBI group (14). Spontaneous alternation percentage in the Y maze did not show any significant differences among groups.

Histopathological changes that include axonal edema, vascular congestion areas, focal neuronal loss, cytoplasmic eosinophilic degeneration, hyperchromasia in the neuronal nucleus, formation of gliotic areas and nuclear pycnosis are the consequences of TBI (15). In this study, the histological damage scores in the cortical, hippocampal DG and CA3 areas were increased with TBI and were significantly decreased in the cortex and DG of the niacin-treated TBI group, but the decrease in the score of CA3 region of niacin-treated TBI group was not significant. The histological damage in TBI + placebo group was similar with our previous studies (7,17,18). The niacin treatment reduced TBI-related histological damage in cortex and hippocampus DG and this finding showed the neuroprotective effect of niacin in acute mild TBI.

There are also limitations for our study. We tried to inhibit the secondary brain injury with immediate niacin administration following TBI. In acute TBI cases this timing may not be possible. Previous niacin supplementation in required cases and an effective blood concentration would benefit more as a public health intervention, since anyone can encounter with TBI in a lifetime, while niacin supplementation would also prevent other neurological diseases. We used 500 mg/kg dose of niacin, but a prolonged release form of niacin (Niaspan) could also be studied, because niacin has a short half-life as 20-45 minutes. Furthermore, larger number of animals per group could be more feasible to show the differences in cognitive functions.



Niacin has a key role in neuronal health and its bioavailability is crucial for neuronal survival after brain injury. In this study, we confirmed that niacin is a potent anti-inflammatory, antioxidant, and neuroprotective agent with potential benefits in behavioral tests. Based on the present findings, clinical evidence is needed and prospective randomized clinical trials are warranted for the use of niacin/Niaspan in daily practice as a neuroprotective and neurorestorative agent in mild TBI.

#### AUTHORSHIP CONTRIBUTION

Study conception and design: PKB, BCY, BG  
 Data collection: DO, PKB, TK, SCO, AKK, DA, CE, MY  
 Analysis and interpretation of results: PKB, DA, BCY  
 Draft manuscript preparation: DO, PKB  
 Critical revision of the article: MY, BCY, BG  
 All authors (DO, PKB, TK, SCO, AKK, DA, CE, MY, BCY, BG) reviewed the results and approved the final version of the manuscript.

#### REFERENCES

1. Antunes M, Biala G: The novel object recognition memory: Neurobiology, test procedure, and its modifications. *Cogn Process* 13(2):93-110, 2012
2. Arik E, Dolgun H, Kuru Bektasoglu P, Ergil J, Coskun Yilmaz B, Tonge C, Ozturk OC, Gurses L, Gurer B: Neuroprotective effect of paeonol in the rat model of traumatic brain injury. *J Ankara Univ Fac Med* 73:42-46, 2020
3. Bederson JB, Pitts LH, Tsuji M, Nishimura MC, Davis RL, Bartkowski H: Rat middle cerebral artery occlusion: Evaluation of the model and development of a neurologic examination. *Stroke* 17(3):472-476, 1986
4. Calvillo M, Irimia A: Neuroimaging and psychometric assessment of mild cognitive impairment after traumatic brain injury. *Front Psychol* 11:1423, 2020
5. Cui X, Chopp M, Zacharek A, Roberts C, Buller B, Ion M, Chen J: Niacin treatment of stroke increases synaptic plasticity and axon growth in rats. *Stroke* 41(9):2044-2049, 2010
6. Darwish H, Hasan H: Y-shaped maze to test spontaneous object recognition and temporal order memory after traumatic brain injury. *Methods Mol Biol* 2011:383-392, 2019
7. Demir D, Kuru Bektasoglu P, Koyuncuoglu T, Kandemir C, Akakin D, Yuksel M, Celikoglu E, Yegen BC, Gurer B: Neuroprotective effects of mildronate in a rat model of traumatic brain injury. *Injury* 50(10):1586-1592, 2019
8. Elmore S: Apoptosis: A review of programmed cell death. *Toxicol Pathol* 35(4):495-516, 2007
9. Ennaceur A, Delacour J: A new one-trial test for neurobiological studies of memory in rats. 1: Behavioral data. *Behav Brain Res* 31(1):47-59, 1988
10. Fricker RA, Green EL, Jenkins SI, Griffin SM: The influence of nicotinamide on health and disease in the central nervous system. *Int J Tryptophan Res* 11:1178646918776658, 2018
11. Ganji SH, Qin S, Zhang L, Kamanna VS, Kashyap ML: Niacin inhibits vascular oxidative stress, redox-sensitive genes, and monocyte adhesion to human aortic endothelial cells. *Atherosclerosis* 202(1):68-75, 2009
12. Gasperi V, Sibilano M, Savini I, Catani MV: Niacin in the central nervous system: An update of biological aspects and clinical applications. *Int J Mol Sci* 20(4):974, 2019
13. Goffus AM, Anderson GD, Hoane M: Sustained delivery of nicotinamide limits cortical injury and improves functional recovery following traumatic brain injury. *Oxid Med Cell Longev* 3(2):145-152, 2010
14. Hoane MR, Akstulewicz SL, Toppen J: Treatment with vitamin B3 improves functional recovery and reduces GFAP expression following traumatic brain injury in rats. *J Neurotrauma* 20(11):1189-1199, 2003
15. Kertmen H, Gurer B, Yilmaz ER, Kanat MA, Arikok AT, Erguder BI, Hasturk AE, Ergil J, Sekerci Z: Antioxidant and antiapoptotic effects of darbepoetin- $\alpha$  against traumatic brain injury in rats. *Arch Med Sci* 11(5):1119-1128, 2015
16. Kinoshita K, Chatzipanteli iK, Vitarbo E, Truettner JS, Alonso OF, Dietrich WD: Interleukin-1 $\beta$  messenger ribonucleic acid and protein levels after fluid-percussion brain injury in rats: importance of injury severity and brain temperature. *Neurosurgery* 51(1):195-203, 2002
17. Knoblach SM, Fan L, Faden AI: Early neuronal expression of tumor necrosis factor- $\alpha$  after experimental brain injury contributes to neurological impairment. *J Neuroimmunol* 95(1-2):115-125, 1999
18. Kuru Bektasoglu P, Koyuncuoglu T, Akbulut S, Akakin D, Eyuboglu IP, Erzik C, Yuksel M, Kurtel H: Neuroprotective effect of plasminogen activator inhibitor-1 antagonist in the rat model of mild traumatic brain injury. *Inflammation* 44(6):2499-2517, 2021
19. Kuru Bektasoglu P, Koyuncuoglu T, Demir D, Sucu G, Akakin D, Peker Eyuboglu I, Yuksel M, Celikoglu E, Yegen BC, Gurer B: Neuroprotective effect of cinnamaldehyde on secondary brain injury after traumatic brain injury in a rat model. *World Neurosurg* 153:e392-e402, 2021
20. Kwon WY, Suh GJ, Kim KS, Jung YS, Kim SH, Lee AR, You KM, Park MJ: Niacin and selenium attenuate brain injury after cardiac arrest in rats by up-regulating DJ-1-Akt signaling. *Crit Care Med* 46(8):e788-e796, 2018
21. Kwon WY, Suh GJ, Kim KS, Lee HJ, Jeong KY, Kwak YH, Kim K: Niacin suppresses the mitogen-activated protein kinase pathway and attenuates brain injury after cardiac arrest in rats. *Crit Care Med* 41(9):e223-232, 2013
22. Lin SH, Chong ZZ, Maiese K: Nicotinamide: A nutritional supplement that provides protection against neuronal and vascular injury. *J Med Food* 4:27-38, 2001
23. Lozano D, Gonzales-Portillo GS, Acosta S, de la Pena I, Tajiri N, Kaneko Y, Borlongan CV: Neuroinflammatory responses to traumatic brain injury: Etiology, clinical consequences, and therapeutic opportunities. *Neuropsychiatr Dis Treat* 11:97-106, 2015
24. Lueptow LM: Novel object recognition test for the investigation of learning and memory in mice. *J Vis Exp* 126:55718, 2017

25. Maas AIR, Menon DK, Adelson PD, Andelic N, Bell MJ, Belli A, Bragge P, Brazinova A, Büki A, Chesnut RM, Citerio G, Coburn M, Cooper DJ, Crowder AT, Czeiter E, Czosnyka M, Diaz-Arrastia R, Dreier JP, Duhaime AC, Ercole A, van Essen TA, Feigin VL, Gao G, Giacino J, Gonzalez-Lara LE, Gruen RL, Gupta D, Hartings JA, Hill S, Jiang JY, Ketharanathan N, Kompanje EJO, Lanyon L, Laureys S, Lecky F, Levin H, Lingsma HF, Maegele M, Majdan M, Manley G, Marsteller J, Mascia L, McFadyen C, Mondello S, Newcombe V, Palotie A, Parizel PM, Peul W, Piercy J, Polinder S, Puybasset L, Rasmussen TE, Rossaint R, Smielewski P, Söderberg J, Stanworth SJ, Stein MB, von Steinbüchel N, Stewart W, Steyerberg EW, Stocchetti N, Synnot A, Te Ao B, Tenovuo O, Theadom A, Tibboel D, Videtta W, Wang KKW, Williams WH, Wilson L, Yaffe K; InTBIR Participants and Investigators: Traumatic brain injury: Integrated approaches to improve prevention, clinical care, and research. *Lancet Neurol* 16(12):987-1048, 2017
26. Maiese K, Chong ZZ: Nicotinamide: Necessary nutrient emerges as a novel cytoprotectant for the brain. *Trends Pharmacol Sci* 24:228-232, 2003
27. Marmarou A, Foda MA, van den Brink W, Campbell J, Kita H, Demetriadou K: A new model of diffuse brain injury in rats. Part I: Pathophysiology and biomechanics. *J Neurosurg* 80(2):291-300, 1994
28. Miedel CJ, Patton JM, Miedel AN, Miedel ES, Levenson JM: Assessment of spontaneous alternation, novel object recognition and limb clasping in transgenic mouse models of amyloid- $\beta$  and tau neuropathology. *J Vis Exp M* 123:55523, 2017
29. Ozay R, Turkoglu ME, Gurer B, Dolgun H, Evirgen O, Erguder BI, Hayirli N, Gurses L, Sekerci Z: The protective effect of omeprazole against traumatic brain injury: An experimental study. *World Neurosurg* 104:634-643, 2017
30. Ozay R, Turkoglu E, Gurer B, Dolgun H, Evirgen O, Erguder BI, Hayirli N, Gurses L, Sekerci Z, Yilmaz ER: Does decorin protect neuronal tissue via its antioxidant and antiinflammatory activity from traumatic brain injury? An experimental study. *World Neurosurg* 97:407-415, 2017
31. Patterson ZR, Holahan MR: Understanding the neuroinflammatory response following concussion to develop treatment strategies. *Front Cell Neurosci* 6:58, 2012
32. Perez-Polo JR, Rea HC, Johnson KM, Parsley MA, Unabia GC, Xu G, Infante SK, Dewitt DS, Hulsebosch CE: Inflammatory consequences in a rodent model of mild traumatic brain injury. *J Neurotrauma* 30(9):727-740, 2013
33. Peterson TC, Anderson GD, Kantor ED, Hoane MR: A comparison of the effects of nicotinamide and progesterone on functional recovery of cognitive behavior following cortical contusion injury in the rat. *J Neurotrauma* 29(18):2823-2830, 2012
34. Peterson TC, Hoane MR, McConomy KS, Farin FM, Bammler TK, MacDonald JW, Kantor ED, Anderson GD: A combination therapy of nicotinamide and progesterone improves functional recovery following traumatic brain injury. *J Neurotrauma* 32(11):765-779, 2015
35. Prince C, Bruhns ME: Evaluation and treatment of mild traumatic brain injury: The role of neuropsychology. *Brain Sci* 7(8):105, 2017
36. Salehi A, Zhang JH, Obenaus A: Response of the cerebral vasculature following traumatic brain injury. *J Cereb Blood Flow Metab* 37(7):2320-2339, 2017
37. Shetty PK, Galeffi F, Turner DA: Nicotinamide pre-treatment ameliorates NAD(H) hyperoxidation and improves neuronal function after severe hypoxia. *Neurobiol Dis* 62:469-478, 2014
38. Swan AA, Chandrashekar R, Beare J, Hoane MR: Preclinical efficacy testing in middle-aged rats: nicotinamide, a novel neuroprotectant, demonstrates diminished preclinical efficacy after controlled cortical impact. *J Neurotrauma* 28(3):431-440, 2011
39. Te Ao B, Brown P, Tobias M, Ameratunga S, Barker-Collo S, Theadom A, McPherson K, Starkey N, Dowell A, Jones K, Feigin VL; BIONIC Study Group: Cost of traumatic brain injury in New Zealand: Evidence from a population-based study. *Neurology* 83(18):1645-1652, 2014
40. Toklu HZ, Uysal MK, Kabasakal L, Sirvanci S, Ercan F, Kaya M: The effects of riluzole on neurological, brain biochemical, and histological changes in early and late term of sepsis in rats. *J Surg Res* 152(2):238-248, 2009
41. Ucar T, Tanriover G, Gurer I, Onal MZ, Kazan S: Modified experimental mild traumatic brain injury model. *J Trauma* 60(3):558-565, 2006
42. Vanderploeg RD, Curtiss G, Belanger HG: Long-term neuropsychological outcomes following mild traumatic brain injury. *J Int Neuropsychol Soc* 11(3):228-236, 2005
43. Vonder Haar C, Anderson GD, Hoane MR: Continuous nicotinamide administration improves behavioral recovery and reduces lesion size following bilateral frontal controlled cortical impact injury. *Behav Brain Res* 224(2):311-317, 2011
44. Vonder Haar C, Maass WR, Jacobs EA, Hoane MR: Deficits in discrimination after experimental frontal brain injury are mediated by motivation and can be improved by nicotinamide administration. *J Neurotrauma* 31(20):1711-1720, 2014
45. Won SJ, Choi BY, Yoo BH, Sohn M, Ying W, Swanson RA, Suh SW: Prevention of traumatic brain injury-induced neuron death by intranasal delivery of nicotinamide adenine dinucleotide. *J Neurotrauma* 29(7):1401-1409, 2012
46. Woodcock T, Morganti-Kossmann MC: The role of markers of inflammation in traumatic brain injury. *Front Neurol* 4:18, 2013
47. Yilmaz ER, Kertmen H, Gurer B, Kanat MA, Arikok AT, Erguder BI, Hasturk AE, Ergil J, Sekerci Z: The protective effect of 2-mercaptoethane sulfonate (MESNA) against traumatic brain injury in rats. *Acta Neurochir (Wien)* 155(1):141-149; discussion 149, 2013